

## Case Report

# Usage of Point-of-care Ultrasonography for Rapid Diagnosis of Acute Renal Infarction: Two Case Reports

CME  
Credits

Yi-Hsin Lai, Cheng-Hsun Chuang, Sai-Wai Ho, Chia-Ching Chen\*

Department of Emergency Medicine, Chung Shan Medical University Hospital, Taichung City, Taiwan

## Abstract

Acute renal infarction is a rare form of vascular emergency. Although major risk factors of renal infarction are due to cardio-embolic events such as atrial fibrillation, valvular or ischemic heart disease, renal artery thrombosis/dissection, and coagulopathy, the prevalence of idiopathic acute renal infarction can be as high as 59%. Two cases that contributed to this emergency are presented. The history, physical examination, and clinical imaging findings for clinical assessment are briefly described. Point-of-Care Ultrasonography (POCUS) was used to exclude other etiology and identify the pathological changes. The role of POCUS in rapid rule in acute renal infarction has been emphasized in clinical settings.

**Keywords:** Acute renal infarction, point-of-care ultrasonography, impaired renal perfusion, CFD sonography

## INTRODUCTION

Renal infarction is a rare condition with published rates of 1.4% for 14,411 autopsies published in 1940<sup>[1]</sup> and 17/250,000 visits at an emergency department (ED).<sup>[2]</sup> The incidence of renal infarction is probably higher since clinical diagnosis of renal infarction is frequently missed or delayed given the fact that its presentation can mimic other more common pathologies such as acute pyelonephritis or renal colic.

In patient with acute flank pain, by recognition of intact corticomedullary differentiation of kidney, absence of urolithiasis, hydronephrosis, hydroureter and excluded other vascular emergencies, the emergency physicians should search evidence of impaired renal perfusion by using power Doppler and color flow Doppler (CFD) or computed tomography (CT) images. CT is the gold standard diagnostic tool. In addition to excluding other etiology of acute flank pain such as urolithiasis and acute pyelonephritis, Point-of-care ultrasonography (POCUS) imaging is useful in rapid detection perfusion deficit of renal cortex, and ascertaining sonographic evidence of renal infarction for rapid diagnosis, making effective treatment in this vascular emergency in early stage.

## CASE REPORT

### Case 1

A 76-year-old male with atrial fibrillation undergoing regular anticoagulation for decades presented with a 2-h history of severe left flank pain, nausea, malaise, and vomiting unresponsive to oral painkiller to our ED. On physical examination, his temperature was 36.8°C, pulse was regular at 69 beats/min, and blood pressure was 185/77 mm Hg. Laboratory studies showed white blood cell count of 9580/ $\mu$ L, hemoglobin level of 15.5 g/dL, C-reactive protein level of 1.3 mg/dL, lactate dehydrogenase level of 154 U/L, and serum creatinine level of 0.98 mg/dL. Urinalysis showed the following: Leukocytes (–), proteinuria (–) and RBC > 100/HPF. POCUS performed immediately after physical examination and intact corticomedullary differentiation of left kidney with the absence of urolithiasis, hydronephrosis, or hydroureter were appreciated [Figure 1a]. Power Doppler images showed absent blood flow to the left upper kidney suggesting acute renal infarction [Figure 1b]. Contrast-enhanced CT [Figure 1c]

**Address for correspondence:** Dr. Chia-Ching Chen,  
Department of Emergency Medicine, Chung Shan Medical University  
Hospital, No. 110, Section 1, Jianguo N. Road, South Dist.,  
Taichung City 402, Taiwan.  
E-mail: c11g@hotmail.com

Received: 12-08-2021 Revised: 28-09-2021 Accepted: 12-11-2021 Available Online: 06-01-2022

### Access this article online

#### Quick Response Code:



**Website:**  
[www.jmuonline.org](http://www.jmuonline.org)

**DOI:**  
10.4103/jmu.jmu\_167\_21

This is an open access journal, and articles are distributed under the terms of the Creative Commons Attribution-NonCommercial-ShareAlike 4.0 License, which allows others to remix, tweak, and build upon the work non-commercially, as long as appropriate credit is given and the new creations are licensed under the identical terms.

**For reprints contact:** WKHLRPMedknow\_reprints@wolterskluwer.com

**How to cite this article:** Lai YH, Chuang CH, Ho SW, Chen CC. Usage of point-of-care ultrasonography for rapid diagnosis of acute renal infarction: Two case reports. J Med Ultrasound 2022;30:300-2.

confirmed the apical segment infarction and parenteral anticoagulation therapy initiated after 1 h of ED arrival. The patient was treated with novel oral anticoagulants (NOACs) during the admission period. Holter monitor showed neither atrial arrhythmia, paroxysmal supraventricular tachycardia (PSVT), nor ventricular arrhythmia. Urine cytology revealed high-grade urothelial carcinoma. The patient received laparoscopic radical nephroureterectomy and the pathology report confirmed urothelial cell carcinoma. He is currently receiving adjuvant chemotherapy.

## Case 2

A 46-year-old male presented with a 1-h history of severe left flank cramping pain to our ED. The patient's medical history was unremarkable. On physical examination, his temperature was 36.4°C, pulse was regular at 68 beats/min, and blood pressure was 99/81 mm Hg. Laboratory studies were unremarkable. POCUS showed intact corticomedullary differentiation of the left kidney with the absence of urolithiasis, hydronephrosis, or hydroureter [Figure 2a]. Power Doppler images showed diminished blood flow to the left middle kidney suggesting acute renal infarction [Figure 2b]. Contrast-enhanced CT [Figure 2c] confirmed the anterior superior segment and anterior inferior segment infarction. The patient was treated with NOACs during the admission period. Neither atrial arrhythmia, PSVT, nor ventricular arrhythmia was ever detected by Holter exam. The patient was diagnosed with idiopathic acute renal infarction. At follow-up 2 months after presentation, the patient's flank pain had fully abated.

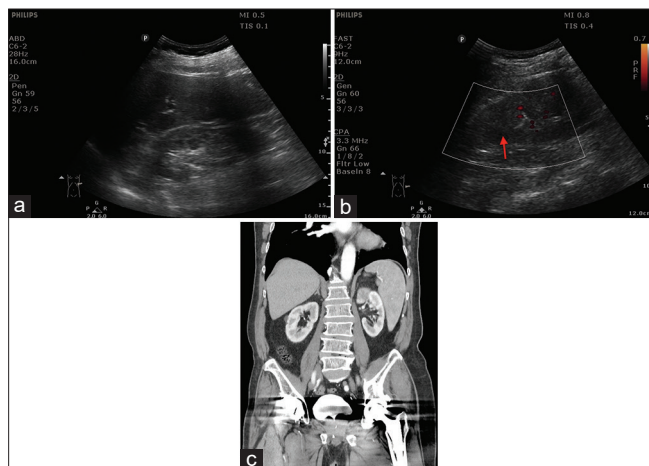
## DISCUSSION

The reported incidence of all causes of renal infarction is approximate 0.004%–0.007%.<sup>[3]</sup> Symptoms of acute renal infarction include abdomen pain and/or flank pain.<sup>[4]</sup> In a study of 18 patients published in 2017, major associated risk factors included hypertension, obesity, atrial fibrillation,

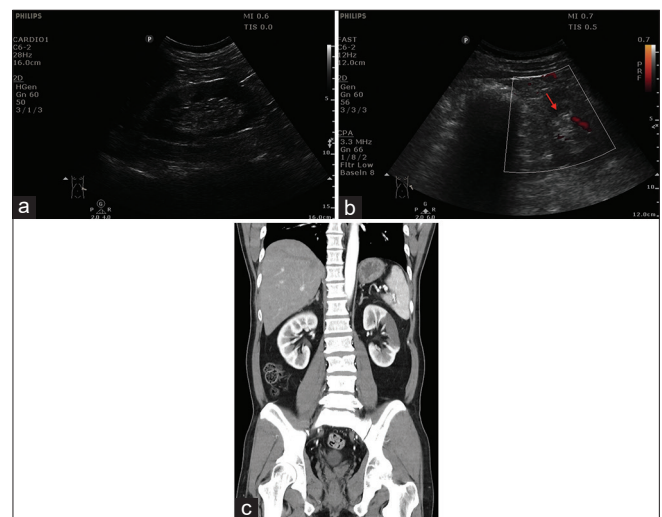
peripheral vascular disease, smoking, prior thromboembolic event, diabetes, estroprogestinic therapy.<sup>[5]</sup> The lack of unique clues for acute renal infarction makes it difficult to diagnose at the early stage of the disease. Typical clinical presentations of acute renal infarction include acute onset of flank or abdominal pain, frequently accompanied by nausea, vomiting, and, occasionally, fever.<sup>[4,6–8]</sup> Acute elevation in blood pressure is a nonspecific physical finding since pain due to urolithiasis or renal colic also makes high blood pressure.

The typical presentation of renal infarction is characterized by a time-dependent progression. At the acute stage, grayscale findings are neither sensitive nor specific for renal infarction. Echogenic wedge-shaped or loss of corticomedullary differentiation is usually appreciated in late stage and cortical thickness is well maintained in the acute stage. CFD sonography allows the visualization of flow direction and velocity within a user-defined area. Low pulse repetition frequencies under CFD may reveal selective low renal blood flow at the acute stage and provide additional evidence of renal infarction<sup>[9]</sup> at the earliest. By recognizing low renal blood flow in patient with acute flank pain.

While CT image remains the gold diagnostic tool for precisely demonstrating acute renal infarction, POCUS is a timely, efficient, effective, and patient-centered alternative in the ED setting. By recognition of intact corticomedullary differentiation of kidney, absence of urolithiasis, hydronephrosis, hydroureter and excluded other vascular emergencies such as aortic dissection or ruptured abdominal aneurysm by POCUS, emergency physicians should search evidence of impaired renal perfusion by using CFD sonography for detecting low blood flows or delineating small areas of infarction. Further CT scan study and anticoagulant therapy as soon as possible for reducing morbidity and minimizing renal sequelae.



**Figure 1:** (a) Left kidney long-axis view showed intact corticomedullary differentiation. (b) Left kidney long-axis view showed absent blood flow to the left upper kidney (red arrow). (c) Computed tomography of the abdomen confirmed left apical segment infarction



**Figure 2:** (a) Left kidney long-axis view showed intact corticomedullary differentiation. (b) Left kidney short-axis view showed diminished blood flow to the left anterior superior segment of kidney (red arrow). (c) Computed tomography of abdomen confirmed anterior superior segment and anterior inferior segment of kidney infarction

### Declaration of patient consent

The authors certify that they have obtained all appropriate patient consent forms. In the form, the patients have given their consent for their images and other clinical information to be reported in the journal. The patients understand that their names and initials will not be published and due efforts will be made to conceal their identity, but anonymity cannot be guaranteed.

### Financial support and sponsorship

Nil.

### Conflicts of interest

There are no conflicts of interest.

### REFERENCES

1. Hoxie HJ, Coggin CB. Renal infarction: Statistical study of two hundred and five cases and detailed report of an unusual case. *Arch Intern Med* 1940;65:587-94.
2. Paris B, Bobrie G, Rossignol P, Le Coz S, Chedid A, Plouin PF. Blood pressure and renal outcomes in patients with kidney infarction and hypertension. *J Hypertens* 2006;24:1649-54.
3. Kwon JH, Oh BJ, Ha SO, Kim DY, Do HH. Renal complications in patients with renal infarction: Prevalence and risk factors. *Kidney Blood Press Res* 2016;41:865-72.
4. Bourgault M, Grimbert P, Verret C, Pourrat J, Herody M, Halimi JM, *et al.* Acute renal infarction: A case series. *Clin J Am Soc Nephrol* 2013;8:392-8.
5. Mesiano P, Rollino C, Beltrame G, Ferro M, Quattrocchio G, Fenoglio R, *et al.* Acute renal infarction: A single center experience. *J Nephrol* 2017;30:103-7.
6. Domanovits H, Paulis M, Nikfardjam M, Meron G, K rkciyan I, Bankier AA, *et al.* Acute renal infarction. Clinical characteristics of 17 patients. *Medicine (Baltimore)* 1999;78:386-94.
7. Hazanov N, Somin M, Attali M, Beilinson N, Thaler M, Mouallem M, *et al.* Acute renal embolism. Forty-four cases of renal infarction in patients with atrial fibrillation. *Medicine (Baltimore)* 2004;83:292-9.
8. Chu PL, Wei YF, Huang JW, Chen SI, Chu TS, Wu KD. Clinical characteristics of patients with segmental renal infarction. *Nephrology (Carlton)* 2006;11:336-40.
9. Saeed K. Renal infarction. *Int J Nephrol Renovasc Dis* 2012;5:119-23.